



41 Mortons neuroma

Contents

- [Introduction](#)
- [Anatomy](#)
- [Biomechanics](#)
- [Clinical Presentation](#)
- [Pathogenesis](#)
- [Physical Examination](#)
- [Imaging](#)
- [Conservative Treatment](#)
- [Operative Treatment](#)
- [Postoperative Care](#)
- [Complications](#)
- [References](#)

41.1 Introduction

Forefoot pain is a common complaint. One of the most frequent causes of this forefoot pain and disability is Morton's neuroma, a paroxysmal neuralgia that presents as a sharp, burning pain in the webspace of, most commonly, the 3rd and 4th toes. It is not a neuroma based on the definition of the word, but is rather a perineural fibrosis.

Historically, Morton's neuroma was first described in 1845 by Queen Victoria's surgeon chiropodist, Lewis Durlacher as a "form of neuralgic affection" involving the distal plantar nerves.¹ Thirty years later, Thomas G. Morton of Philadelphia described this disorder (incorrectly) as a capsulitis of the 4th metatarsophalangeal joint, although he accurately described the disorder's symptomatology.² In 1883, Hoadley was the first surgeon to actually excise the interdigital neuroma as a treatment for Morton's neuroma.³ Then in 1940, L.O. Betts confirmed that Morton's neuroma pain was attributed to a swelling of the interdigital nerve.⁴

The epidemiology of the disease is not clearly defined, as the incidence and prevalence are not known.⁵ Typically, women ages 45-50 are affected, and although men are also affected, women account for the overwhelming majority of cases.^{5,6} Both feet are equally affected, although bilateral complaints are rare. It is also uncommon to find two neuromas in the same foot.

The differential diagnosis must be carefully crafted to exclude more serious disorders of the forefoot. The differential diagnosis for Morton's neuroma includes:^{7,8}

- Intermetatarsal bursitis
- Metatarsophalangeal joint instability/capsulitis

- Stress fracture
- Metatarsalgia
- Lumbar radiculopathy
- Tarsal tunnel syndrome
- Stress fracture
- [Frieberg's infraction](#)
- Infection
- Tumors
- Painful callosities associated with toe deformities
- Peripheral neuropathy

41.2 Anatomy

Morton's neuroma affects the third interdigital nerve in the third webspace between the third and fourth toes (80-85% of cases) and the second common digital nerve in the second webspace (10-15% of cases).⁷ There may be an anatomic and biomechanic reason for the frequency of the involvement of the third common digital nerve in Morton's neuroma.

- Firstly, the common digital nerve of the third webspace is the largest digital nerve and is usually a confluence of the terminal branches of the medial and lateral plantar nerves (the two terminal divisions of the tibial nerve) (Figure 1).

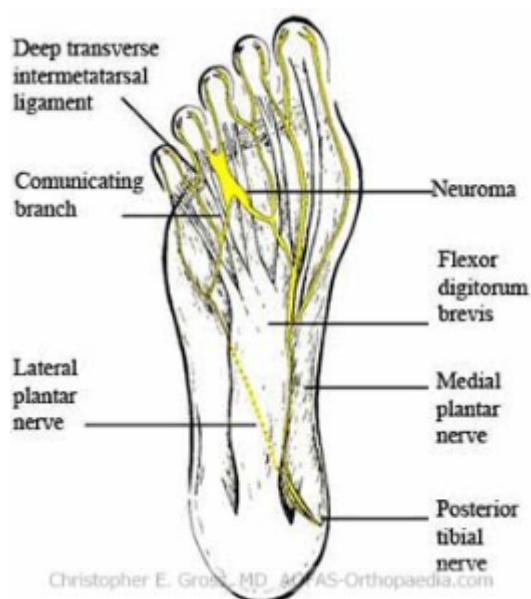

Figure 1. Plantar anatomy

- Secondly, the space that the nerve occupies is subject to shearing forces as the relatively mobile 4th metatarsal can stress the nerve against the relatively fixed 3rd metatarsal.
- Thirdly, the nerve may experience compression during use of high-heeled shoe-wear. These shoes reduce the support of the weight-bearing portion of the foot to the forefoot, which causes hyperextension of the metatarsophalangeal joints, compressing the common digital nerve and metatarsal heads against the tough and unwielding intermetatarsal ligament.

41.3 Biomechanics

The neuroma itself is usually densely adherent to the intermetatarsal ligament. It is part of the neurovascular bundle, which is fusiform in shape.⁴ The tissue itself is usually a soft-yellow or whitish glistening soft mass. (Figure 2) Histologically, there is evidence of fibroblast and Schwann cell proliferation, represented by extensive juxta- and intraneural fibrosis as well as perivascular and subintimal fibrosis.⁸ There is demyelination and axonal damage. Additionally, Renaut bodies (subperineural hyalinized nodules) are present.

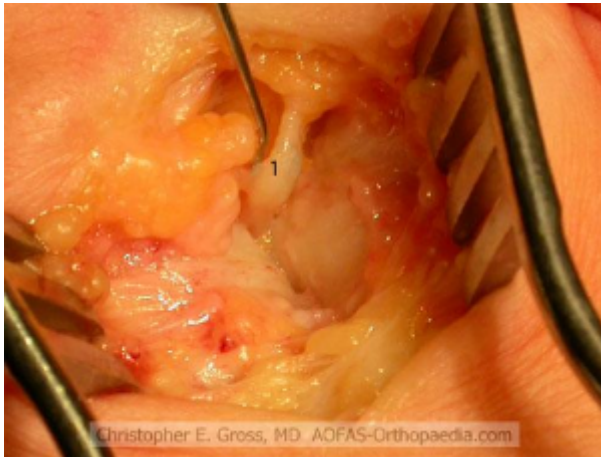


Figure 2. Intra-operative image of Morton's neuroma as a fusiform swelling of the nerve

41.4 Clinical Presentation

A careful history and physical examination must be made to exclude other pathologies in the differential diagnosis. A patient with a Morton's neuroma often complains of a burning, sharp pain located in between the third and fourth toes. This pain is often plantar at the metatarsal heads and radiates distally on either side of the toe; it can also radiate from the forefoot up the leg proximally. The pain is exacerbated with wearing tight or constricted shoes and alleviated while walking barefoot. A patient may describe characteristically and temporally different pain. The first, intense pain lasts for about 5-10 minutes and is precipitated by direct compression of the neuroma. This pain then becomes a dull ache for the next 2-3 hours.^{4,8} One feature of a Morton's neuroma is that a patient may need to rest after walking, remove the shoe, and massage the area of discomfort for moderate relief.¹¹ This may occur several times throughout the day. Patients may also complain of the sensation of a stone or pebble under the toes or forefoot when walking.

41.5 Pathogenesis



The exact etiology and pathogenesis of Morton's neuroma is still a point of contention. Morton suggested that enlargement or a neuroma of the digital branches of the lateral plantar nerve was the source of pain.² Neuritis has also been suggested.⁹ Betts speculated that the contraction of the flexor digitorum brevis caused the nerve to shear against the intermetatarsal ligament, which in turn causes inflammation. Another theory popularized by Nissen states that the intermetatarsophalangeal bursa balloons out, causing traction on the digital nerve adjacent to the digital nerve. This leads to an ischemic effect on the nerve.¹⁰ Current theories postulate that Morton's neuroma is a consequence of the combination of repetitive mechanical and ischemic trauma, entrapment, and tethering.⁸

41.6 Physical Examination

As mentioned above, included in the differential diagnosis for Morton's neuroma are metatarsalgia, metatarsophalangeal synovitis/instability, stress fracture of the phalanges or metatarsals, Freiberg's infraction, infection, and tumors. A thorough physical examination is essential in differentiating among these possible diagnoses.

- Metatarsalgia will present with more plantar pain at the metatarsal head (usually 2nd or 3rd).
- A stress fracture may be ascertained with a history of trauma/overuse and pain with activity; the pain can be reproduced over the fracture site.
- Freiberg's infraction usually occurs in adolescent females with dorsal pain over the 2nd metatarsal head.
- Clinical suspicion for infection and tumors must always remain high. Areas of ulceration and erythema may point to infection.

On visualization, the patient's foot is often unremarkable, without signs of intermetatarsal bursitis or dorsal bulging. On palpation, the usual location of pain is at the interspace between the metatarsal heads. Therefore, one must examine the metatarsophalangeal joints for synovitis or instability (metatarsophalangeal drawer test). Interdigital skin sensation is often decreased.

A useful test for Morton's neuroma is the "lateral squeeze test". This test is performed with the index and thumb on the dorsal and plantar aspect of the painful intermetatarsal space. The forefoot is then compressed with the opposite hand by squeezing together the metatarsal heads. The test is positive if a painful or palpable click is felt. This "Mulder's click" is likely due to subluxation of the neuroma between the metatarsal heads.¹²

41.7 Imaging

Morton's neuroma is usually a clinical diagnosis made on a thorough history and physical examination. Imaging may be necessary to rule out the differential diagnosis listed above. Occasionally, an X-ray may show a faint radiopaque mass and lateral toe deviation.⁸ MRI (Figure 3) and ultrasonography (Figure 4) may also confirm a Morton's neuroma. An MRI will show inflammation surrounding the neuroma, as seen in T2-weighted images. An ultrasound will show a non-compressible hypoechoic interdigital mass with or without a bursal effusion.

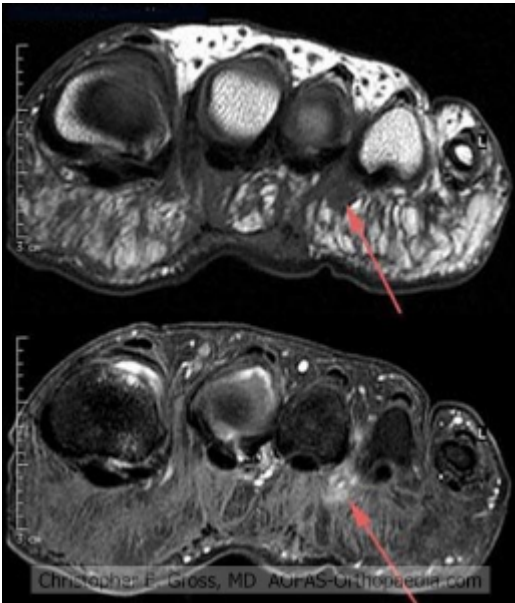


Figure 3. MRI of Morton's neuroma

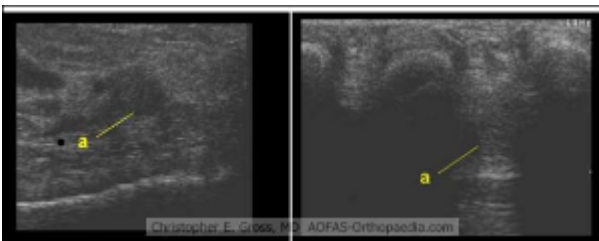


Figure 4. Longitudinal and transverse ultrasound views of Morton's neuroma

While early studies of imaging showed that the clinical utility of these modalities is questionable,¹³ most studies did not evaluate a Morton's neuroma with today's more sensitive MRI magnets and ultrasonography equipment. Owens and colleagues showed that an MRI may have a sensitivity of 97% in patients with symptomatic neuromas, but showed neuromas in 25% of patients without symptoms.¹⁴ Sharp et al evaluated 29 confirmed cases of Morton's neuroma that were evaluated with an MRI, ultrasound, and physical examination. MRI and ultrasound's accuracy was dependent on the size of the lesions. Physical exam proved to be the most sensitive and specific modality.¹⁵

41.8 Conservative Treatment

When a diagnosis of Morton's neuroma is made, some surgeons believe that conservative management is never warranted because the pain will persist and worsen as the neuroma enlarges.⁴ However, several conservative treatment modalities are available. There is no agreed-upon treatment algorithm, but most believe that these treatments should be tried from 3 months to 1 year.^{7,8}

Firstly, a patient should wear wide, comfortable shoes with a large toe box.⁷ Their shoes should be low-heeled and may be supplemented with either a metatarsal pad or a custom orthotic. The pads help to relieve metatarsal head pressure. The custom orthotics seek to limit foot subtalar pronation, which should theoretically limit the mobility of the first ray and reduce forefoot abduction.¹⁶ Unfortunately, a randomized trial failed to show any subjective pain differences between the pronated orthotic group and the control group.¹⁶



Secondly, a person may try to decrease the neuroma pain and inflammation with non-steroidal anti-inflammatory medications. Physical therapy has also been used.¹⁷ Ultrasound, whirlpool, massage, and electrical stimulation are often used, although their efficacy has not been studied.

Another treatment modality is an intermetatarsal corticosteroid and local anesthetic injection. It is imperative that the needle traverses the intermetatarsal ligament to enter the bursa and infiltrate the neurovascular bundle. While some studies show that 47% of people may experience relief with injections,¹⁸ others fail to show any long-term relief.¹⁹ Recently, studies have looked at injection of either phenol or alcohol. An electrode-guided injection of phenol proved to be effective in 80.3% of cases.²⁰ Ultrasound-guided injection of alcohol gave 84% of patients total relief, with partial relief to 94%.²¹ However, there is evidence that this relief is not long-term, with many having surgery several years later for recurrent pain.²² The evidence for conservative therapies is relatively weak.⁵ If a patient fails these measures, surgery is warranted. Relative contraindications include uncontrolled diabetes, complex regional pain syndrome, and vascular dysfunction.

41.9 Operative Treatment

Many surgical methods have been described including:^{5,7}

- Interdigital nerve excision with intermetatarsal ligament division, with or without submuscular transposition
- Isolated intermetatarsal ligament division
- Isolated interdigital nerve excision

The patient is usually given regional anesthesia with sedation. A thigh or ankle tourniquet is used to prevent bleeding.

41.9.1 Dorsal Approach

A dorsal incision is made in the interspace between the affected metatarsals. The 3- to 4-cm longitudinal incision is taken down through the skin and subcutaneous tissues. One must take care to identify and retract away the dorsal sensory branch of the intermediate dorsal cutaneous branch of the superficial peroneal nerve.⁷

Dissection is then bluntly continued down to the level of the intermetatarsal ligament. A small lamina spreader is inserted between the metatarsal heads to facilitate exposure and to place the ligament under tension. A Freer elevator is placed beneath the intermetatarsal ligament and transected with a scalpel or scissors, protecting the underlying neurovascular structures.

The neuroma is then identified between the metatarsal heads adherent to the intermetatarsal bursa. The neuroma is pulled distally such that the nerve trunk can be divided as proximally as possible with long scissors. The distal branches of the nerve are then dissected. The remaining nerve trunk may be treated with phenol, followed by isopropyl alcohol to prevent the recurrence of a neuroma.

41.9.2 Plantar Approach



The plantar approach is often used in cases of neuroma recurrence, as it provides better visualization of the proximal nerve trunk. A plantar excision is made just proximal to the webspace and extends at least 4 cm proximally. The incision is extended between the metatarsal heads to avoid scarring the bony prominences. Strands of the fibrous plantar tissue must be divided. The neuroma is usually located subcutaneously, and is then resected as described above.

41.10 Postoperative Care

A compression dressing is applied and a post-operative shoe is placed on the foot. A dorsal approach allows for immediate weight-bearing and suture removal after 2 weeks. A plantar incision delays weight-bearing and suture removal for 2 more weeks.⁷ A patient usually transitions to a normal shoe by 3-4 weeks, with return to sports in 4-6 weeks.

41.11 Complications

The most common complication results from wound healing, keloid formation, or superficial infection.⁸ In one series, 1.1% of patients had a wound infection, while 2.2% had keloid formation over the scar.⁸

Recurrent neuroma formation is another complication. This results from inadequate proximal resection of the common digital nerve. This neuroma is then trapped by the metatarsal heads, compressed, and causes pain. In re-operation for recurrent neuroma, one may bury the stump in the intrinsic musculature of the foot.

Despite the above complications, patients describe high satisfaction rates from 80% to 96%.^{18,23}

41.12 References

1. Durlacher L. A treatise on corns, bunions, the diseases of nails, and the general management of feet: Marshall and Co; 1945.
2. Morton TG. The Classic. A peculiar and painful affection of the fourth metatarso-phalangeal articulation. Thomas G. Morton, M.D. *Clinical orthopaedics and related research* 1979;4-9.
3. Hoadley AE. Six cases of metatarsalgia. *Chicago Med Rec* 1893;5:32.
4. Grace D. The Lesser Rays. In: Helal BR, D; Cracchiolo, A; Myerson, M, ed. *Surgery of Disorders of the Foot and Ankle*. London: Lipincott-Raven; 1996:348-51.
5. Thomson CE, Gibson JN, Martin D. Interventions for the treatment of Morton's neuroma. *Cochrane Database Syst Rev* 2004;CD003118.
6. Thompson C CR, Wood, A, Rendall G. *Disorders of the adult foot*. 6th ed. Edinburgh: Churchill Livingstone; 2001.
7. Singh A IJ, Chiodo C. The surgical treatment of Morton's neuroma. *Current Orthopaedics* 2005;19:379-84.
8. Wu KK. Morton's interdigital neuroma: a clinical review of its etiology, treatment, and results. *The Journal of foot and ankle surgery : official publication of the American College of Foot and Ankle Surgeons* 1996;35:112-9; discussion 87-8.
9. Betts L. Morton's metatarsalgia. *Med J Aust* 1940;1:514-5.



10. Nissen KI. Plantar digital neuritis; Morton's metatarsalgia. *The Journal of bone and joint surgery British volume* 1948;30B:84-94.
11. Lutter L. *Atlas of adult foot and ankle surgery*. St. Louis, Missouri: Mosby; 1997.
12. Mulder JD. The causative mechanism in morton's metatarsalgia. *The Journal of bone and joint surgery British volume* 1951;33-B:94-5.
13. Resch S, Stenstrom A, Jonsson A, Jonsson K. The diagnostic efficacy of magnetic resonance imaging and ultrasonography in Morton's neuroma: a radiological-surgical correlation. *Foot & ankle international / American Orthopaedic Foot and Ankle Society [and] Swiss Foot and Ankle Society* 1994;15:88-92.
14. Owens R, Gougoulas N, Guthrie H, Sakellariou A. Morton's neuroma: clinical testing and imaging in 76 feet, compared to a control group. *Foot and ankle surgery : official journal of the European Society of Foot and Ankle Surgeons* 2011;17:197-200.
15. Sharp RJ, Wade CM, Hennessy MS, Saxby TS. The role of MRI and ultrasound imaging in Morton's neuroma and the effect of size of lesion on symptoms. *The Journal of bone and joint surgery British volume* 2003;85:999-1005.
16. Kilmartin TE, Wallace WA. Effect of pronation and supination orthosis on Morton's neuroma and lower extremity function. *Foot & ankle international / American Orthopaedic Foot and Ankle Society [and] Swiss Foot and Ankle Society* 1994;15:256-62.
17. Nunan PJ, Giesy BD. Management of Morton's neuroma in athletes. *Clinics in podiatric medicine and surgery* 1997;14:489-501.
18. Bennett GL, Graham CE, Mauldin DM. Morton's interdigital neuroma: a comprehensive treatment protocol. *Foot & ankle international / American Orthopaedic Foot and Ankle Society [and] Swiss Foot and Ankle Society* 1995;16:760-3.
19. Rasmussen MR, Kitaoka HB, Patzer GL. Nonoperative treatment of plantar interdigital neuroma with a single corticosteroid injection. *Clinical orthopaedics and related research* 1996:188-93.
20. Magnan B, Marangon A, Frigo A, Bartolozzi P. Local phenol injection in the treatment of interdigital neuritis of the foot (Morton's neuroma). *La Chirurgia degli organi di movimento* 2005;90:371-7.
21. Hughes RJ, Ali K, Jones H, Kendall S, Connell DA. Treatment of Morton's neuroma with alcohol injection under sonographic guidance: follow-up of 101 cases. *AJR American journal of roentgenology* 2007;188:1535-9.
22. Ramesh P, Gurdezi S, White T, et al. [Alcohol Injection for Morton's Neuroma: Does it Really Hit the Spot? - A 5 Year Follow-up](#). Podium Presentation Number 507, American Academy of Orthopaedic Surgeons Annual Meeting, February 17, 2011, San Diego, CA.
23. Mann RA, Reynolds JC. Interdigital neuroma--a critical clinical analysis. *Foot & ankle* 1983;3:238-43.